



IJPI's Journal of Pharmacology and Toxicology

Visit

www.ijpijournals.com

A Protective effect of *Caesalpinia sappan* (CS) on acetaminophen induced nephrotoxicity and oxidative stress in male *albino* rats

K.Sarumathy^{a&c*}, T.Vijay^{a&b}, J.Jayakanthi^a, M.S.Dhana Rajan^d

^aResearch and development centre, Bharathiar university, Coimbatore-641 046

^bP.G & Research Dept. of Biochemisry, KMG College of Arts & Science,
Gudiyattam Vellore dist., Tamil Nadu, India

^cP.G & Research Dept. of Biochemisry, DKM College for Women,
Vellore, Tamil Nadu India.

^dDept of Biochemistry Jaya college of Arts & Science, Tiruninravur, Chennai-602 024

* Corresponding Author: K.Sarumathy

Email address: vcharujee@gmail.com

ABSTRACT:

Caesalpinia sappan (CS) is a traditional medicinal plant that is widely distributed in India and other Asian countries. It is used in traditional Indian medicine as an emenagogue, emostatic and anti-inflammatory agent, as well as for the treatment of contusion and thrombosis. *C.sappan* has also been reported for its various biological activities such as antioxidative, anti-inflammatory, immunostimulant, hypoglycemic, antimicrobial, antifungal, analgesic and hepatoprotective properties. Phytoconstituents like 1, 2, 3, 5-Cyclohexanetetrol, 3-O-Methyl-d-glucose, 1, 2-Benzenedicarboxylic acid, diisooctyl ester were identified as high % peak when compared with other compounds by GC-MS. The aim of this study was to examine the nephroprotective and antioxidant activities of ethanol extract of CS at two dose levels of 100 and 200 mg/kg B/W on acetaminophen (APAP) induced toxicity in male *albino* rats. APAP significantly reduced levels of uric acid and increased levels of serum urea, creatinine. Ethanolic extract CS significantly increased activities of renal superoxide dismutase, catalase, and glutathione peroxidase and decreased Malondialdehyde content of APAP treated rats.

In addition to that histopathological changes also showed the defensive nature of the CS extract against APAP induced necrotic damage of renal tissues. In conclusion it was observed that the ethanol extract of CS conferred nephroprotective and antioxidant activities by histopathological and biochemical observations against APAP induced renal damage in rats

Key words; *Caesalpinia sappan*, nephrotoxicity, oxidative stress, acetaminophen.

1. INTRODUCTION

Acetaminophen (APAP) belongs to a class of drugs called analgesics (pain relievers) and antipyretics (fever reducers) it is safely employed for a wide range of treatments (1), overdose of APAP in human is fairly common and is often associated with hepatic (2) and renal damage (3). Although nephrotoxicity is less common than hepatotoxicity in APAP overdose, renal tubular damage and acute renal failure can occur even in the absence of liver injury (4) and can even lead to death in humans and experimental animals (5).

Studies are going on throughout the world for the search of protective molecules that would provide maximum protection to the liver, kidney as well as other organs and practically very little or no side effects would be exerted during their function in the body (6). Plants are one of the most important sources of medicines. Today the large number of drugs in use is derived from plants.

Caesalpinia sappan (Caesalpiniaceae) is used in traditional Indian medicine as an emenagogue, emostatic and anti-inflammatory agent, as well as for the treatment of contusion and thrombosis. The heartwood of *C.sappan* has also been reported for its various biological activities such as antioxidative, anti-inflammatory, immunostimulant (7) cytotoxic, hypoglycemic, (9) antimicrobial (9), antifungal (11), analgesic (9) and hepatoprotective (7) properties, which are attributed to the presence of phenolic compounds, homoisoflavones etc., (13). The *Caesalpinia sappan* heartwoods have been used as a red dye for a long time. Several members of the species *Caesalpinia* are being used traditionally for a wide variety of ethnomedical properties. Several flavonoids, phenols (14), triterpenoids (15), and steroids have been isolated from the heartwood. In previous studies, sappanchalcone, brazilin, brazilin, brazilin, protosappanin A, protosappanin B, protosappanin C, protosappanin E, hematein, and hematoxylin were isolated in the methanol extract of *C. sappan* (16). Brazilin, a phenolic oxygen heterocycle is found to be the major constituents. However, no recent studies are contributed on the Nephroprotective and antioxidant properties of this plant extract. Therefore, this study was designed to identify the protective effects of the ethanolic extracts of *Caesalpinia sappan* against acetaminophen induced nephrotoxicity and antioxidant activities.

2. MATERIALS AND METHODS

Plant material:

Aerial part of *Caesalpinia sappan* (Caesalpiniaceae) was collected from Tirunelveli district, Tamil Nadu, India in the month of March. The plant material was taxonomically identified and authenticated by V.Chelladurai (Research Officer) Botany (C.C.R.A.S) Government of India. Voucher specimen (DKMC02/2009-2010) has been retained in the PG & Research Department of Biochemistry, D.K.M College for Women, Vellore-632 001, and Tamilnadu, India.

Extraction:

The aerial part of *Caesalpinia sappan* was dried under shade and then powdered with a mechanical grinder to obtain a coarse powder. Equal quantity of powder was passed through 40 mesh 91 sieve and extracted with ethanol (90% v/v) in soxhlet apparatus at 60°C (8). The solvent was completely removed by rotary vacuum evaporator. The extract was freeze dried and stored in a vacuum desiccator.

2.2 Identification of Phytochemicals in CS extract (GC-MS Study)

The identification of the chemical composition of ethanol extract of CS was performed using a GC-MS spectrograph (Agilent 6890/Hewlett-Packard 5975) fitted with electron impact (EI) mode. The ethanol extract (2.0 µl) of CS was injected with a Hamilton syringe to the GC-MS manually for total ion chromatographic analysis in split mode. In

quantitative analysis, selected ion monitoring (SIM) mode was employed during the GC–MS analysis. SIM plot of the ion current resulting from very small mass range with only compounds of the selected mass were detected and plotted.

2.3 Animals:

Studies were carried out using Wistar albino male rats (150-200g), obtained from Indian Veterinary Preventive medicine (IVPM), Ranipet, Tamilnadu, India. The animals were grouped and housed in polyacrylic cages (38 x 23 x10 cm) with not more than six animals per cage and maintained under standard laboratory conditions temperature $25 \pm 2^{\circ}\text{C}$) with dark and light cycle (12/12 h). The animals were fed with standard pellet diet supplied by Poultry Research Station, Nandhanam, India and fresh water *ad libitum*. All the animals were acclimatized to laboratory condition for a week before commencement of experiment. All procedures described were reviewed and approved by the University Animals Ethical Committee.

2.4 Safety evaluation study

Acute oral toxicity studies were performed (Ecobichon, 1997) according to OECD-423 guidelines (acute toxic class method). Swiss mice (n = 3) of either sex selected by random sampling technique were employed in this study. The animals were fasted for 4 h with free access to water only. The CS (suspended with 2% w/v gum acacia) was administered orally at a dose of 5 mg/ kg initially and mortality was observed for 3 days. If mortality was observed in 2/3 or 3/3 animals, then the dose administered was considered as toxic dose. However, if the mortality was observed in only one mouse out of three animals then the same dose was repeated again to confirm the toxic effect. If mortality was not observed, the procedure was then repeated with higher doses, such as 50, 300 and 2000 mg/kg.

2.5 Experimental induction acetaminophen-induced nephrotoxicity

Fasted rats were randomly divided into 5 groups of 6 rats each such that the weight difference within and between group does not exceed $\pm 20\%$ of the average weight of the total rats. Group I rats that served as the untreated control were administered single daily dose of 10 mL of distilled water orally, while group II rats that served as the treated or model control were administered single daily dose of 10 ml distilled water and 750 mg/kg via the oral routes, respectively. Groups III and IV were pretreated with single oral dose of 100 and 200 mg/kg of *Caesalpinia sappan* extract 1 hour before the administration of 750 mg/kg of acetaminophen. Group V animals were treated with *Caesalpinia sappan* 500 mg/kg only

2.6 Sampling and biochemical analysis:

Following termination of the experiment on the day 7, the rats were fasted overnight for 14 hours. Blood samples were collected by cardiac puncture with 21G needle mounted on 5 ml syringe (under diethyl ether anesthesia) and centrifuged for 10min at 2000 rpm. The obtained clear sera were stored at -20°C for subsequent measurement of blood urea, creatinine and uric acid levels using colorimetric assay kits, Bayer (Seamon) according to the manufacturer's instructions.

2.7 Preparation of renal homogenate:

The kidneys were removed and dissected free from the surrounding fat and connective tissue. Each kidney was longitudinally sectioned, and renal cortex was separated and kept at -8°C . Subsequently, renal cortex was homogenized in cold potassium phosphate buffer (0.05 M, pH 7.4). The renal cortical homogenates were centrifuged at 2000 rpm for 10 min at 4°C . The resulting supernatant was used for the determination of malondialdehyde (MDA) content, reduced antioxidant enzyme levels such as super oxide dismutase (SOD), catalase (CAT), glutathione reductase (GRD) and glutathione peroxidase (GPX) activity using colorimetric assay.

2.8 Biochemical estimation of markers of oxidative stress:

MDA content was measured according to the earlier method reported (9). SOD activity was determined according to the previous report (10) CAT activity was determined from the rate of decomposition of H₂O₂ by the reported method (11). GPx activity was determined by measuring the decrease in GSH content after incubating the sample in the presence of H₂O₂ and NaN₃ (12). Glutathione reductase activity was assayed according to the previous reports (13-14). Protein content in the tissue was determined by the method reported earlier (15) using bovine serum albumin (BSA) as the standard.

2.9 Histopathological examination:

Pieces of kidney from each group were fixed immediately in 10% neutral formalin for a period of at least 24 h, dehydrated in graded (50–100%) alcohol, embedded in paraffin, cut into 4–5 µm thick sections and stained with hematoxylin–eosin. The sections were evaluated for the pathological symptoms of nephrotoxicity such as necrosis, fatty infiltration, fibrosis, lymphocyte infiltration, etc.

3. RESULTS

3.1 Phytochemical analysis

The ethanol extract of CS was a complex mixture of many constituents and 12 compounds were identified in this plant by GC–MS. Phytoconstituents such as Propane, 1,1,3-triethoxy-2- Furancarboxaldehyde, 5-(hydroxymethyl), Bicyclo[7.2.0]undec-4-ene, 4,11,11-trimethyl-8-methylene-, [1R-(1R*,4Z,9S*)]-, Naphthalene, 1,2,3,5,6,8a-hexahydro-4,7-dimethyl-1-(1-methylethyl)-, (1S-cis)- [Synonyms: Cadina-1(10),4-diene], Caryophyllene oxide, 1,2,3,5-Cyclohexanetetrol, (1à,2à,3à,5à)-, 3-O-Methyl-d-glucose, 1,2-Benzenedicarboxylic acid, diisooctyl ester, 4,7,10,13,16,19-Docosahexaenoic acid, methylester, (all-Z)-Cyclodecacyclotetradecene, 14,15-didehydro-4,5,8,9,10,11,12,13,16,17,18,19,20-tetradecahydro, 9,12,15-Octadecatrienoic acid, 2-[(trimethylsilyl)oxy]-1-[[[(trimethylsilyl)oxy]methyl]ethyl ester, (Z,Z,Z)-

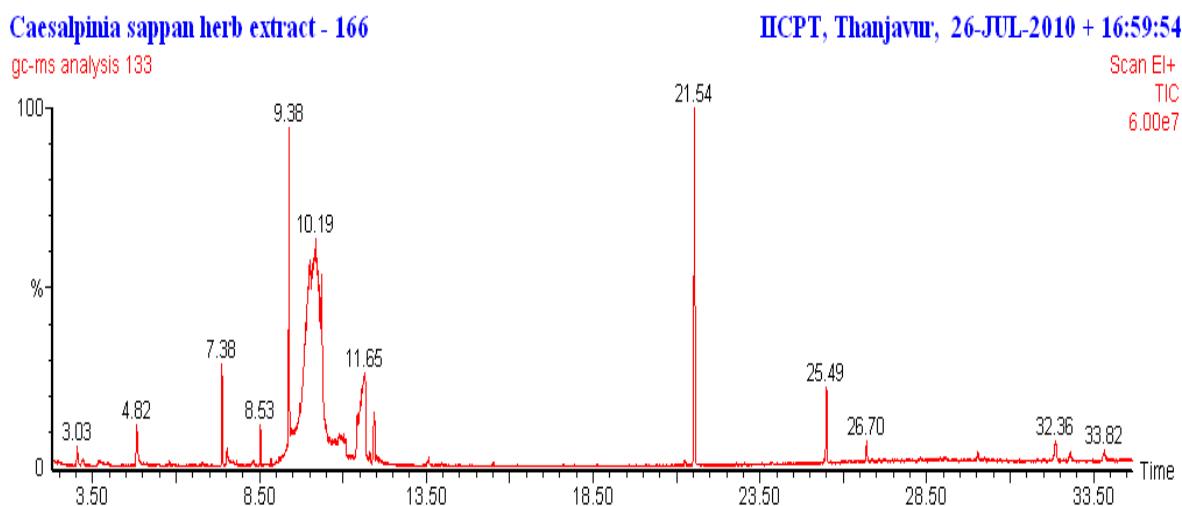


Fig 1: The chromatogram showing 1, 2, 3, 5-Cyclohexanetetrol (49.35), 3-O-Methyl-d-glucose (15.77), 1,2-Benzenedicarboxylic acid (13.78), and Caryophyllene oxide (8.01) peaks detected by GC-MS.

Table 1

Activity of Components identified in *Caesalpinia sappan* ethanol extract
[GC MS study]

No.	RT	Name of the compound	Molecular Formula	MW	Peak Area %	Compound Nature
1.	3.03	Propane, 1,1,3-triethoxy-	C ₉ H ₂₀ O ₃	176	0.68	Ether compound
2.	4.82	2-Furancarboxaldehyde, 5-(hydroxymethyl)-	C ₆ H ₆ O ₃	126	2.67	Aldehyde compound
3.	7.38	Bicyclo[7.2.0]undec-4-ene, 4,11,11-trimethyl-8-methylene-, [1R-(1R*,4Z,9S*)]-	C ₁₅ H ₂₄	204	2.79	Sesquiterpene
4.	8.53	Naphthalene, 1,2,3,5,6,8a-hexahydro-4,7-dimethyl-1-(1-methylethyl)-, (1S-cis)- [Synonyms: Cadina-1(10),4-diene]	C ₁₅ H ₂₄	204	0.93	Sesquiterpene
5.	9.38	Caryophyllene oxide	C ₁₅ H ₂₄ O	220	8.01	Sesquiterpene oxide
6.	10.19	1,2,3,5-Cyclohexanetetrol, (1à,2á,3à,5á)-	C ₆ H ₁₂ O ₄	148	49.35	Poly Hydroxy compound
7.	11.65	3-O-Methyl-d-glucose	C ₇ H ₁₄ O ₆	194	15.77	Sugar moiety
8.	13.57	n-Hexadecanoic acid	C ₁₆ H ₃₂ O ₂	256	0.25	Palmitic acid
9.	21.54	1,2-Benzenedicarboxylic acid, diisooctyl ester	C ₂₄ H ₃₈ O ₄	390	13.78	Plasticizer compound
10.	25.49	4,7,10,13,16,19-Docosahexaenoic acid, methyl ester, (all-Z)-	C ₂₃ H ₃₄ O ₂	342	3.10	Essential fatty acid compound
11.	26.70	Cyclodecacyclotetradecene, 14,15-didehydro-1,4,5,8,9,10,11,12,13,16,17,18,19,20-tetradecahydro-	C ₂₂ H ₃₂	296	0.87	Hydrocarbon
12.	32.36	9,12,15-Octadecatrienoic acid, 2-[(trimethylsilyl)oxy]-1-[[[(trimethylsilyl)oxy]methyl]ethyl ester, (Z,Z,Z)-	C ₂₇ H ₅₂ O ₄ Si ₂	496	1.80	Ester compound

3.2 Acute oral toxicity

CS extract did not produce any mortality even at the highest dose (2000 mg/kg, p.o.) employed. All the doses (5, 50 and 300 mg/kg, p.o.) of TPE were thus found to be non-toxic. Three doses (100, 200 and 400 mg/kg) of TPE were selected for further psychopharmacological and biochemical studies.

Serum urea and creatinine concentrations were significantly increased ($p < 0.01$) in the APAP treated group of animals compared to the normal animals indicating the induction of severe nephrotoxicity. Treatment with the ethanol extract of *Caesalpinia sappan* showed significant ($p < 0.05$ and $p < 0.01$) (Group III and IV) decrease in concentrations of serum urea and creatinine compared to the APAP treated group (Table 2). However the levels of uric acid (UA) significantly decreased ($p < 0.01$) in the APAP treated groups (Group II), when compared to the control group. Treatment with ethanol extract of *Caesalpinia sappan* significantly ($p < 0.05$ and $p < 0.01$) (Group III and IV respectively) increased the uric acid levels, compared to the APAP treated group.

Table 2. Effect of ethanol extract of *Caesalpinia sappan* on serum enzymes Urea (UR), Uric acid (UA) and Creatinine (CR) on acetaminophen induced nephrotoxicity in rats.

Parameters	Group I- Control (NaCl 0.9% w/v)	Group II- Acetaminophen (750mg/kg)	Group III- CS + Acetaminophen (250mg/kg +750mg/kg)	Group IV- CS + Acetaminophen (500mg/kg +750mg/kg)	Group V CS (200mg/kg) alone
Urea (UR) (UR; mM/L)	7.46± 0.25	13.34 ± 0.88**	11.57 ± 0.64*	9.34 ± 0.83**	7.36±0.43
Uric acid (UA) (µM/L),	134.78 ± 6.37	101.34 ± .22**	118.42 ± 4.22*	122.48±6.24**	132.43±5.34
Creatinine (CR) (µM/L)	54.54 ± 4.31	87.76 ± 2.34**	72.21 ± 2.14*	64.36 ± 3.24**	53.46 ± 2.12

All Values are mean ± S.D. ($n = 6$). ** $p < 0.01$, * $p < 0.05$, respectively. with respect to control. (One way ANOVA followed by Dunnett's t-test.)

The activity of CAT in the APAP treated group was significantly ($p < 0.01$) decreased when compared to the normal animals (Group I). Treatment with the ethanol extract of *Caesalpinia sappan* significantly ($p < 0.05$ and $p < 0.01$)

(Group III and IV) prevented decrease in the level of catalase activity (Table 3) compared to the APAP induced rat (Group II). Like wise, the decreased GPx activity as a result of the treatment with APAP was also restored by the *Caesalpinia sappan* extract ($p < 0.05$ and $p < 0.01$) (Figure 2) for Group III and IV as compared to the normal group. Renal SOD activity was decreased significantly ($p < 0.01$) in the APAP treated (group II) animals compared to normal group. Treatment with the ethanol extract of *Caesalpinia sappan* (100 and 200 mg/kg body wt) (Group III and IV) significantly ($p < 0.05$ and $p < 0.01$ respectively) elevated the SOD levels as compared to the APAP induced (Group II) animals (Table 3). The GSH and MDA levels of APAP and extract treated animals are presented in. The GSH level reduced significantly ($p < 0.01$) along with increased in MDA concentration in the APAP treated group as compared to the Group I. However on treatment with *Caesalpinia sappan* ethanol extract, the GSH level was found to be enhanced significantly ($p < 0.05$ and $p < 0.01$) and the MDA contents were reduced in Group III and IV as compared to the induced group (Group II) (Table 3).

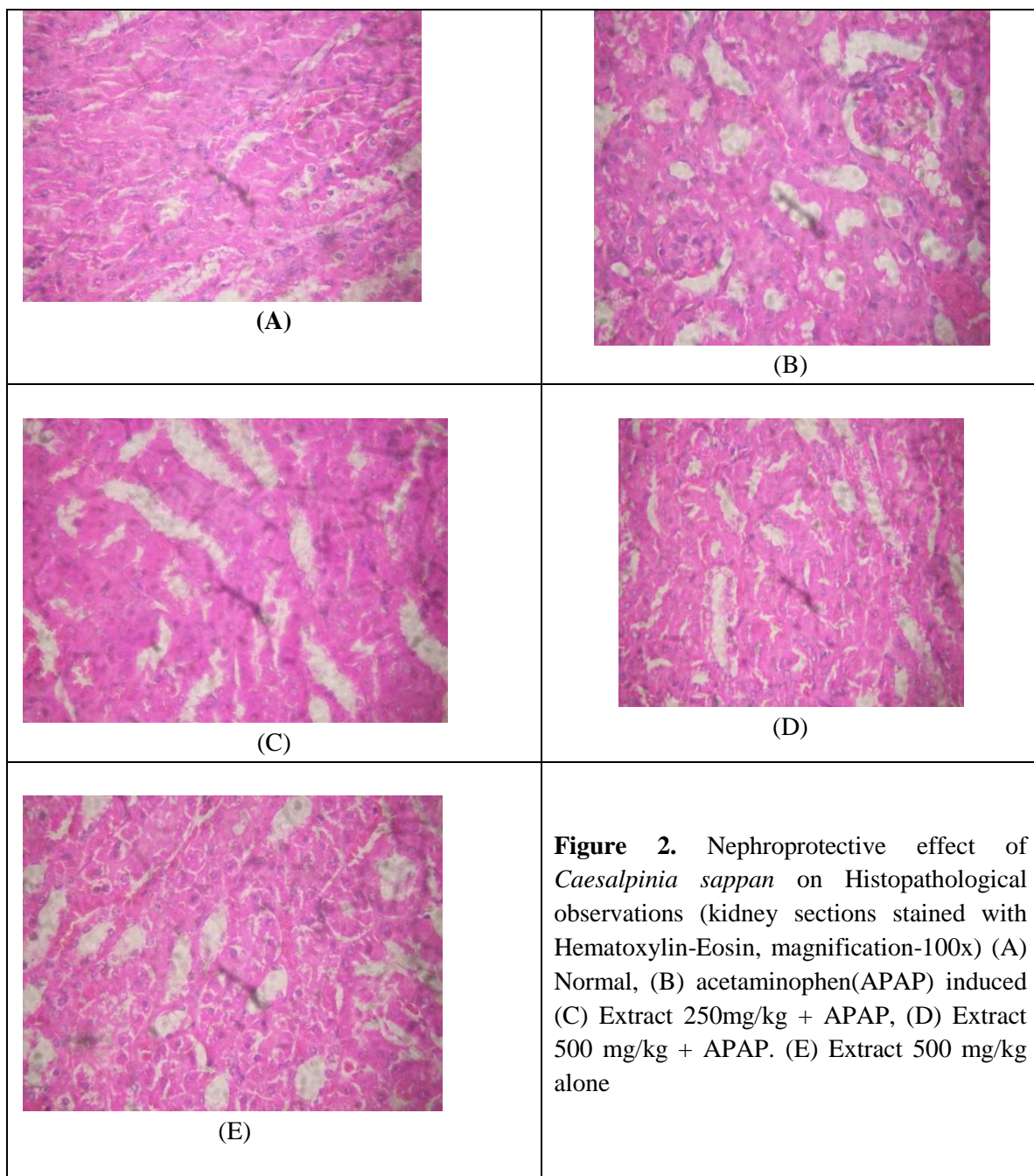
Table 3. Effect of ethanol extract of *Caesalpinia sappan* on antioxidants levels (SOD, CAT, MDA, , and GPX & GST) in acetaminophen induced nephrotoxicity in rats.

Parameters	Group I- Control (NaCl 0.9% w/v)	Group II- Acetaminophe n (750mg/kg)	Group III- CS + Acetaminop hen (100mg/kg +750mg/kg)	Group IV- CS + Acetaminophe n (200mg/kg +750mg/kg)	Group V CS (200mg/kg) alone
SOD(units of activity/mg protein)	0.85± .02	0.62 ±0.32 *	0.72 ± 0.02*	0.81 ± 0.021**	0.82± 0.24
CAT (micromoles of H ₂ O ₂ decomposed/mg protein/min)	20.52 ± .43	10.6 ± .28**	14.20 ± .24*	19.32 ± 0.76 *	20.14 ± 1.32
LP (nanomoles of MDA formed/mg protein/h)	136.54 ± 5.32	176.62 ± 12**	151.43 ± 4.32*	128.54 ± 54**	130.54 ± 6.22
GPX (micrograms of glutathione utilized/min/mg protein)	5.82 ± 0.12	3.24 ± 0.42**	4.12 ± 0.34*	6.14 ± 0.28**	5.78 ± 0.43
GST(Units/mg protein)	0.42±0.06	0.21±0.06**	0.39±0.08*	0.40±0.04**	0.41±0.06

All Values are mean ± S.D. ($n = 6$). ** $p < 0.01$, * $p < 0.05$, respectively. with respect to control. (One way ANOVA followed by Dunnett's t-test.)

3.3 Histopathological studies:

The biochemical results were also confirmed by the histological pattern of normal kidney showing normal tubular brush borders and intact glomeruli and Bowman's capsule (Figure 2 (A)). Treatments with acetaminophen sever tubular necrosis and degeneration has shown in the renal tissue (Figure 2 (B)). The rats treated with ethanolic extract of *Caesalpinia sappan* (100mg/kg body weight) showed normal tubular pattern with a mild degree of swelling, necrosis and degranulation (Figure 2(C) treatments with the extract (200 mg/kg body weight) ameliorated the toxic manifestations in the kidney (Figure 2 (D)). whereas administration of CS (200mg/kg) alone did not show any Significant changes in the renal tissues [Fig 2(E)].



--	--

4.DISCUSSION

Acetaminophen over dose is often linked to many metabolic disorders including serum electrolyte, urea and creatinine dearrangements. Increased concentration of serum urea and creatinine are considered for investigating drug induced nephrotoxicity in animals and man. (16). Blood urea nitrogen is found in the liver protein that is derived from diet or tissue sources and is normally excreted in the urine. In renal disease, the serum urea accumulates because the rate of serum urea production exceeds the rate of clearance (17). Elevation of urea and creatinine levels in the serum was 96 taken as the index of nephrotoxicity (16&18).

Creatinine, on the other hand, is mostly derived from endogenous sources by tissue creatinine breakdown (18). Thus serum urea concentration is often considered a more reliable renal function predictor than serum creatinine. In the present study, administration of hepatotoxic and nephrotoxic doses of APAP to rats resulted in development of oxidative stress damage in hepatic and renal tissues. In this study, APAP induced nephrotoxicity showed a significant ($P<0.01$) increase in the serum urea and creatinine concentrations in the Group II (APAP induced) rat when compared to the normal group (Group I). Moreover, oral administration of ethanolic extract of *Caesalpinia sappan* significantly ($P<0.01$) decreased in group III and IV when compared to the Group II. However the level of uric acid is significantly decreased ($P<0.01$) in the Group II rats when compared to Group I. Oral administration of plant extract significantly ($P<0.01$) increases the uric acid level in Group I when compared to the APAP induced rats (Group II). Thus, oxidative stress and lipid per oxidation are early events related to radicals generated during the hepatic metabolism of APAP. Also the generation of reactive oxygen species has been proposed as a mechanism by which many chemicals can induce nephrotoxicity (19). Previous studies have clearly demonstrated that acute APAP overdose increases the lipid peroxidation and suppresses the antioxidant defense mechanisms in renal tissue (20-21).

However in the APAP treated animals the MDA levels are increased significantly, when compared to normal control rats. On administration of ethanol extract of *Caesalpinia sappan* on the levels of MDA decreased significantly when compared to APAP induced rats. During kidney injury, superoxide radicals are generated at the site of damage and modulate SOD and CAT, resulting in the loss of activity and accumulation of superoxide radical, which damages kidney. SOD and CAT are the most important enzymes involved in ameliorating the effects of oxygen metabolism (22-23). The present study also demonstrated that acute APAP overdose resulted in a decrease in the SOD, CAT and GST activities, when compared with normal control rats. It is due to enhanced lipid peroxidation or inactivation of the antioxidative enzymes. When rat was treated with the ethanol extract of CS the reduction of SOD, CAT and GST activity was increased significantly when compared with induced group ($P<0.01$) (Group II). Current evidence suggests that intracellular GSH plays an essential role in detoxification of APAP and prevention of APAP-induced toxicity in the liver and kidney (24-26). However, APAP was found to increase the microsomal superoxide and hydrogen peroxide production in mice. The generation of the reactive oxygen species appears as an early event which precedes intracellular GSH depletion and cell damage in APAP hepatotoxicity (27). APAP administration also caused a significant decrease in GSH content. Administration of ethanol extract of CS helped to uplift the GSH depletion induced by APAP. APAP induced nephrotoxicity was evidenced by biochemical measurements and Histopathological changes that coincide with the observations of other investigators (28-30). The biochemical results were also confirmed by the histological findings which showed preservation of the glomeruli and the surrounding Bowman's capsule and mildly swollen tubules. Other nephroprotective medicinal plants have been reported of inhibiting xenobiotic-induced nephrotoxicity in experimental animal models 97 due to their potent anti-oxidant or free radicals scavenging effects (31-32). In addition, alkaloids have also been reported to strongly inhibit lipid peroxidation induced in isolated tissues

via its antioxidant activity (33). The Protection offered by the extract could have been due to the presence of alkaloids (34). The activity elicited by the extract might be due to its ability to activate antioxidant enzymes. The findings suggest the potential use of the ethanolic extract of CS as a novel therapeutically useful nephroprotective agent. Therefore, further studies to elucidate their mechanisms of action should be conducted to aid the discovery of new therapeutic agents for the treatment of renal diseases.

5.REFERENCE:

- (1)Yapar, K., Kart, A., Karapehliyan, M., Atakisi, O., Tunca, R., Erginsoy, S. and Cital M. (2007). Hepatoprotective effect of l-carnitine against CSute Acetaminophen toxicity in mice. *Exp. and Toxicolo Pathology* 59: 121-128.
- (2) Nelson, S.D. (1995). Mechanisms of the formation and disposition of reCSstive metabolites that can cause CSute liver injury. *Drug Metab. Rev.* 27:147-177.
- (3)Palani S, Raja S, Naresh R, Kumar BS.(2010) Evaluation of nephroprotective, diuretic, and antioxidant activities of plectranthus amboinicus on acetaminophen-induced nephrotoxic rats.Toxicol mech Methods20(4):213-21.
- (4) Jones, A.F. and Vale, J.A. (1993). Paracetamol poisoning and the kidney. *J. Clin. Pharm. Ther.* 18: 5-8.
- (5) Webster, P.A., Roberts, D.W., Benson, R.W. and Kearns, G.L. (1996). Acetaminophen toxicity in children diagnostic confirmation using specific antigen biomaker. *J. Clin. PhamCSol.* 36: 397-402.
- (6)Mansour, H.H., Hafez, H.F. and Fahmy, N.M. (2006). Silymarin modulates Cisplatin-induced oxidative stress and hepatotoxicity in rats. *J. Biochem. Mol. Biol.* 39: 656-661.
99
- (7) Choi, S. Y.; Yang, K. M.; Jeon, S. D.; Kim, J. H.; Khil, L. Y.; Chang, T. S.; Moon, C. K. 1997*Planta Med.*, 63: 405-408.
- (8) Chattopadhyay, R.R. (2003). Possible mechanism of hepatoprotective Activity of *Azadirachta indica* leaf extractst: Part II. *J. Ethpharmacol.* 89: 217-219.
- (9)Zhang, X.Z. (1992). Crop Physiology Research Methods. China Agricultural Press Beijing. pp 131-207.*Received: 21.05.2009CScepted: 19.10.2009.*
- (10) Rai, S., Wahile, A., Mukherjee, K., Saha, B.P. and Mukherjee, P.K. (2006). Antioxidant Activity of Nelumbonucifera [sCSred lotus] seeds. *J. EthnopharmCSol.* 104: 322-27.
- (11)Bergmeyer, H.U., Gowehn, K. and Grassel, H. In: Bergmeyer, H.U. (1974). Methods of enzymatic analysis. *Weinheim Verlag Chemine.* pp 438-439.
- (12) Hafemann, D.G., Sunde, R.A. and Houestra, W.G. (1974). Effect of dietary selenium on erythrocyte and liver glutathione peroxidase in the rat. *J. Nutr.* 104: 580-584.
- (13) Carlberg, I., Mannervik, B. (1975). Glutathione reductase levels in rat brain. *J. Biol. Chem.* 250: 5475-5479.

- (14) Mohandas, J., Marshall, J.J., Duggin, G.G., Horvath, J.S. and Tiller, D. (1984). Differential distribution of glutathione and glutathione related enzymes in rabbit kidney: possible interCSStions in analgesic neuropathy. *Cancer Re.* 44: 5086-5091.
- (15) Lowry, O.H., Rosebrough, N.J., Farr, A.L. and Randal, R.J. (1951). Protein measurement with the folin phenol reagent. *J. Biol. Chem.* 193: 265-275.
- (16) Bennit, W.M., Parker, R.A., Elliot, W.C., Gilbert, D. and Houghton, D. (1982). Sex related differences in the susceptibility of rat to gentamicin nephrotoxicity. *J. Infec. Diseases* 145: 370-374.
- (17) Mayne, P.D. (1994). The kidneys and renal calculi. In: Clinical chemistry in diagnosis and treatment. 6th ed. London: Edward Arnold Publications. pp 2-24.
- (18) Anwar, S., Khan, N.A., Amin, K.M.Y. and Ahmad, G. (1999). Effects of Banadiq-al Buzoor in some renal disorders
- (19) Somani, S.M., Husain, K., Whitworth, C., Trammell, G.L., Malafa, M. and Rybak, L.P. (2000). Dose-dependent protection by lipoicCSid against cisplatin-induced nephrotoxicity in rats: antioxidant defense system. *PharmCSol. Toxicol.* 86: 234-241.
- (20) Abdel-Zaher, O.A, Abdel-Rahman, M.M., Hafez, M.M. and Omran, F.M. (2007). Role of nitric oxide and reduced glutathione in the protective effects of aminoguanidine, gadolinium chloride and oleanolic CSid against acetaminophen-induced hepatic and renal damage. *Toxicology* 243: 124-134.
- (21) Ghosh, A. and Sil, P.C. (2007). Anti-oxidative effect of a protein from *Cajanus indicus* L. against Acetaminopheninduced hepato-nephro toxicity. *Biochem. Mol. Biol.* 40: 1039-1049.
- (22) Pande, M. and Flora, S.J. (2002). Lead induced oxidative damage and its response to combined administration of alpha-lipoic CSid and succimers in rats. *Toxicology* 177: 187-196.
- (23) Linares, M.V., Bellés, M, Albina, M.L., Sirvent, J.J, Sánchez, D.J et al. (2006). Assessment of the pro-oxidant Activity of uranium in kidney and testis of rats. *Toxicol Lett.* 167: 152-161.
- (24) Newton, J., Hoefle ,D., Gemborys, M., Mugege, G. and Hook, J. (1996). Metabolism and excretion of a glutathione conjugate of Acetaminophen in the isolated rat kidney. *J. PharmCSol. Exp. Ther.* 237: 519-524.
- (25) Richie, Jr.J.P., Long, C.A. and Chen, T.S. (1992). Acetaminophen-induced depletion of glutathione and cysteine in aging mouse kidney. *Biochem. Pharmacol.* 44: 129-135.
- (26) Nelson, S.D. (1990). Molecular mechanisms of hepatotoxicity caused by Acetaminophen. *Semin. Liver Dis.* 10: 267- 278.
- (27) Manov, I, Hirsh, M. and Ianccu, T.C. (2003). Acetaminophen hepatotoxicity and mechanisms of its protection by NCSetylcysteine: a studyof Hep3B cells. *Exp. Toxicol. Pathol.* 53: 489-200.

- (28) Corcoran, G., RCS, W., Smith, G., Mitchell, J. (1985). Effect of NCSetylcysteine on Acetaminophen covalent binding and hepatic necrosis in mice. *J. PharmCSol. Exp. Ther.* 232: 864–872.
- (29) Gardner, C.R., Laskin, J.D., Dambach, D.M., SCSco, M, Durham, S.K et al. (2002). Reduced hepatotoxicity of Acetaminophen in mice lacking inducible nitric oxide synthase: potential role of tumor necrosis factor-alpha and interleukin-10. *Toxicol. Appl. Pharmacol.* 184: 27–36.
- (30) Newton, J.F., Bailie, M.B. and Hook, J.B. (1983). CSctaminophen nephrotoxicity in the rat. Renal metabolic CStivation in vitro. *ToxicoI. Appl. PhannCSO.* 170: 433-444.
- (31) Devipriya, S. and Shyamaladevim, C.S. (1999). Protective effect of quercetin in cisplatin induced cell injury in the rat kidney. *Ind. J. PharmCSol.* 31: 422-426.
- (32) Annie, S, Rajagopal, P.L. and Malini, S. (2005). Effect of *Cassia auriculata* Linn. root extractst on cisplatin and gentamicin-induced renal injury. *Phytomedicine.* 12: 555-560.
- (33) Kumaran, A. and Karunnakaran, R.J. (2007). *In vitro* antioxidant CStivities of methanol extractsts of *Phyllanthus amarus* species from India. *LWT-Swiss Society of Food Science and Technology* 40: 344-352.
- (34) Talapatra, S.K., BhattCSharya, M., Talapatra, B., Das, B.C. (1968). *J. Indian. Chem. Soc.* 45: 861.